http://www.rad.washington.edu/atlas/

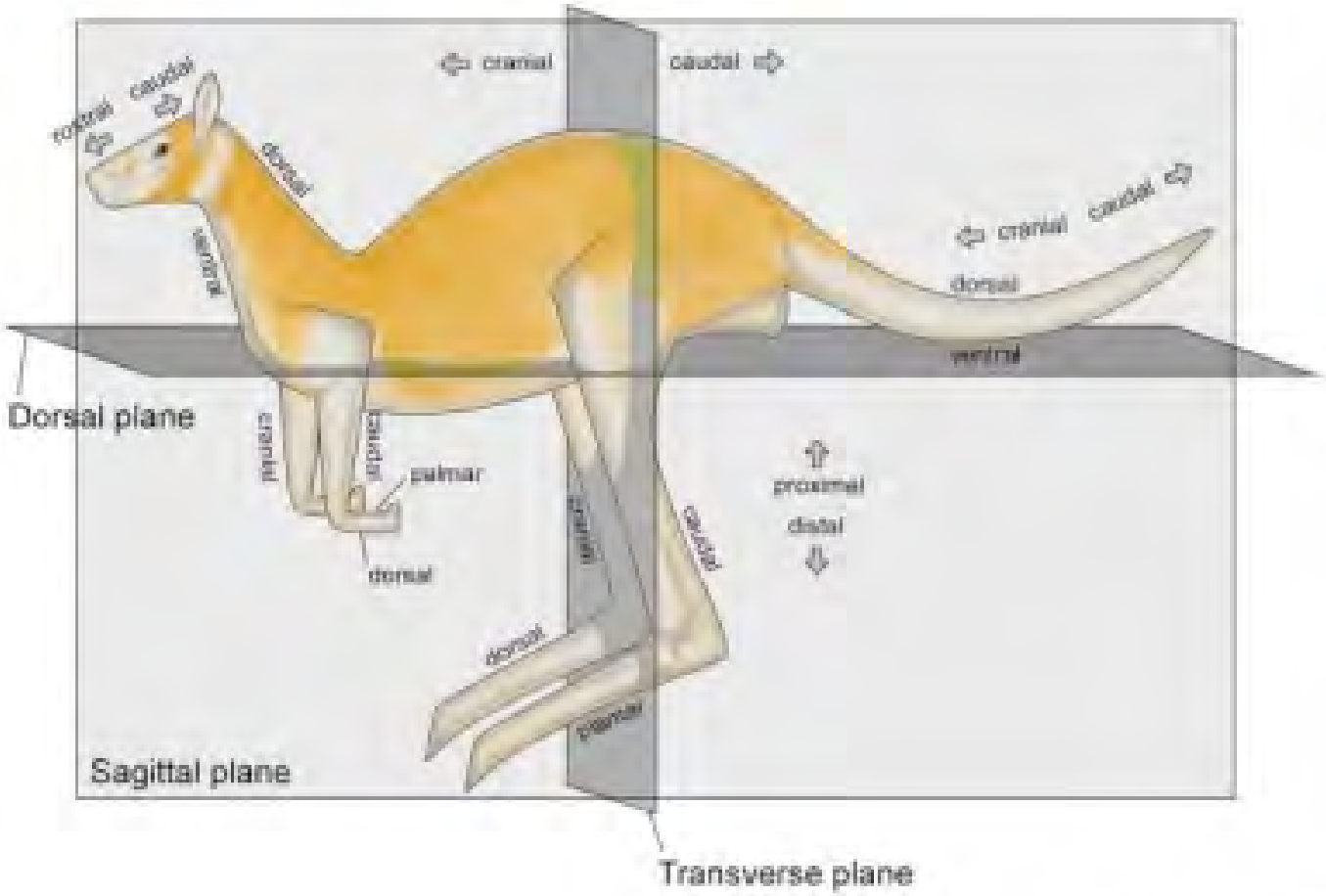
cranial
caudal
rostral
caudal
dorsal
ventral
cranial
caudal
dorsal
ventral
Dorsal plane
cranial
caudal
palmar
dorsal
proximal
distal
cranial
caudal
dorsal
palmar
Sagittal plane
Transverse plane

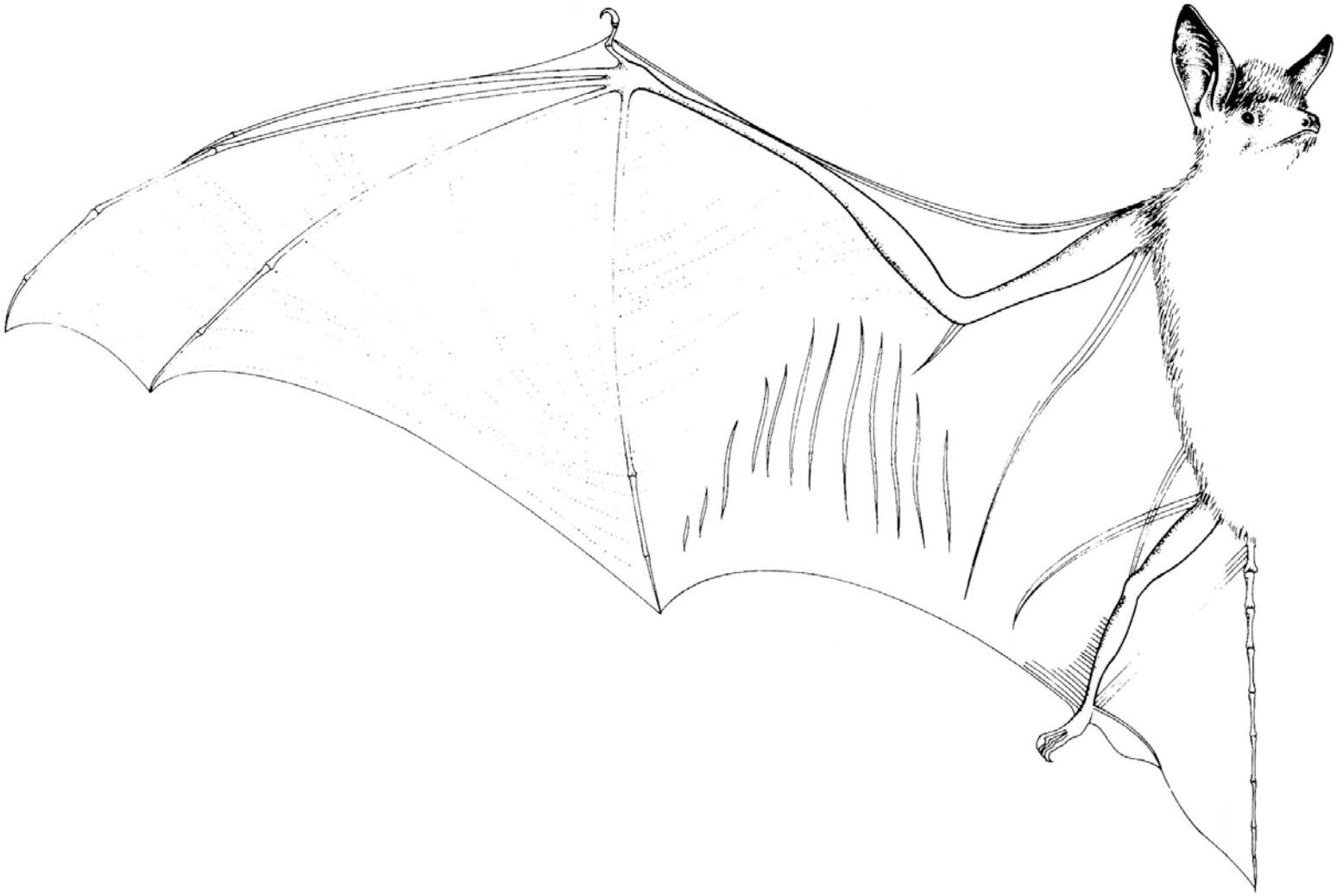

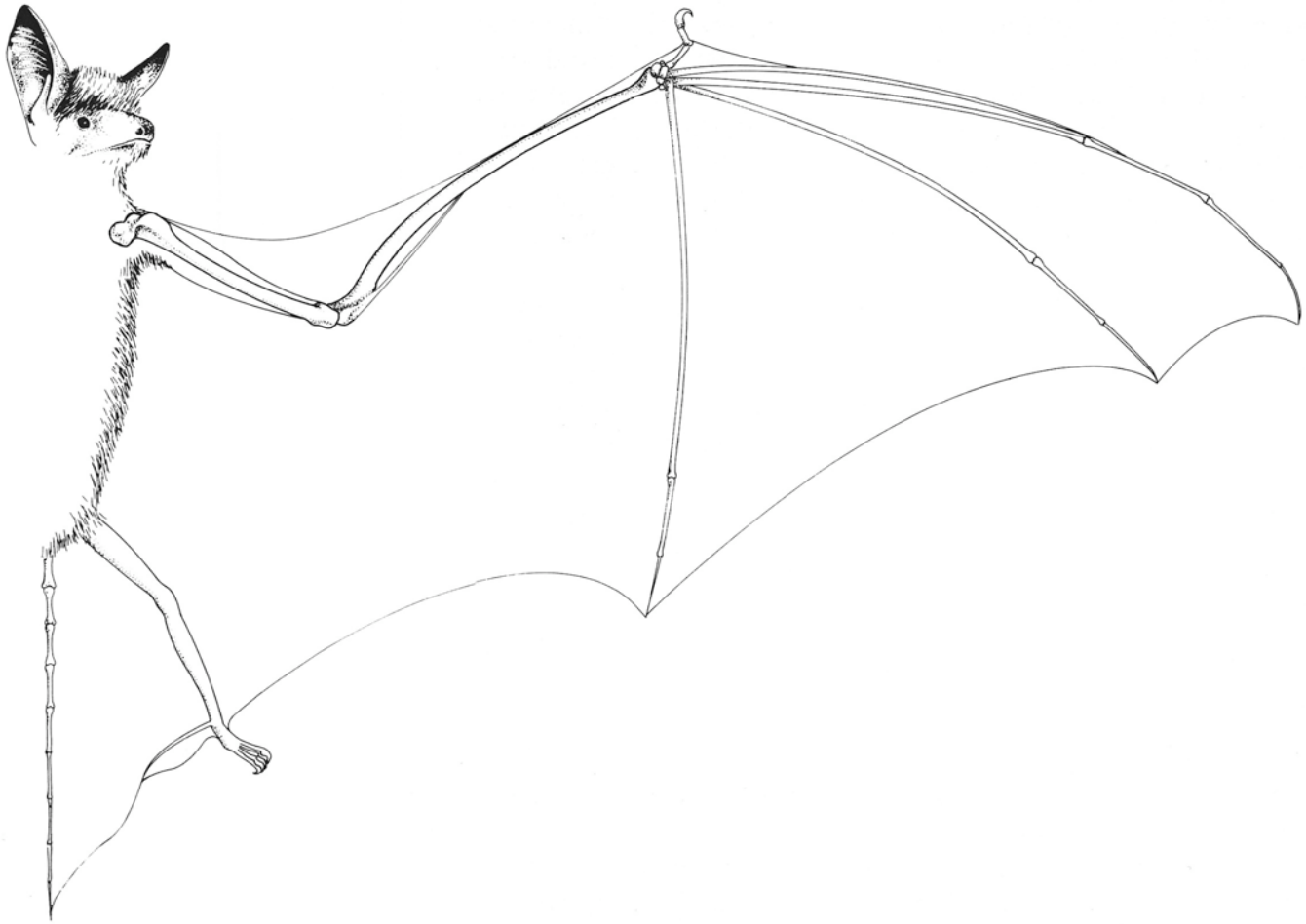

Fig. 1.

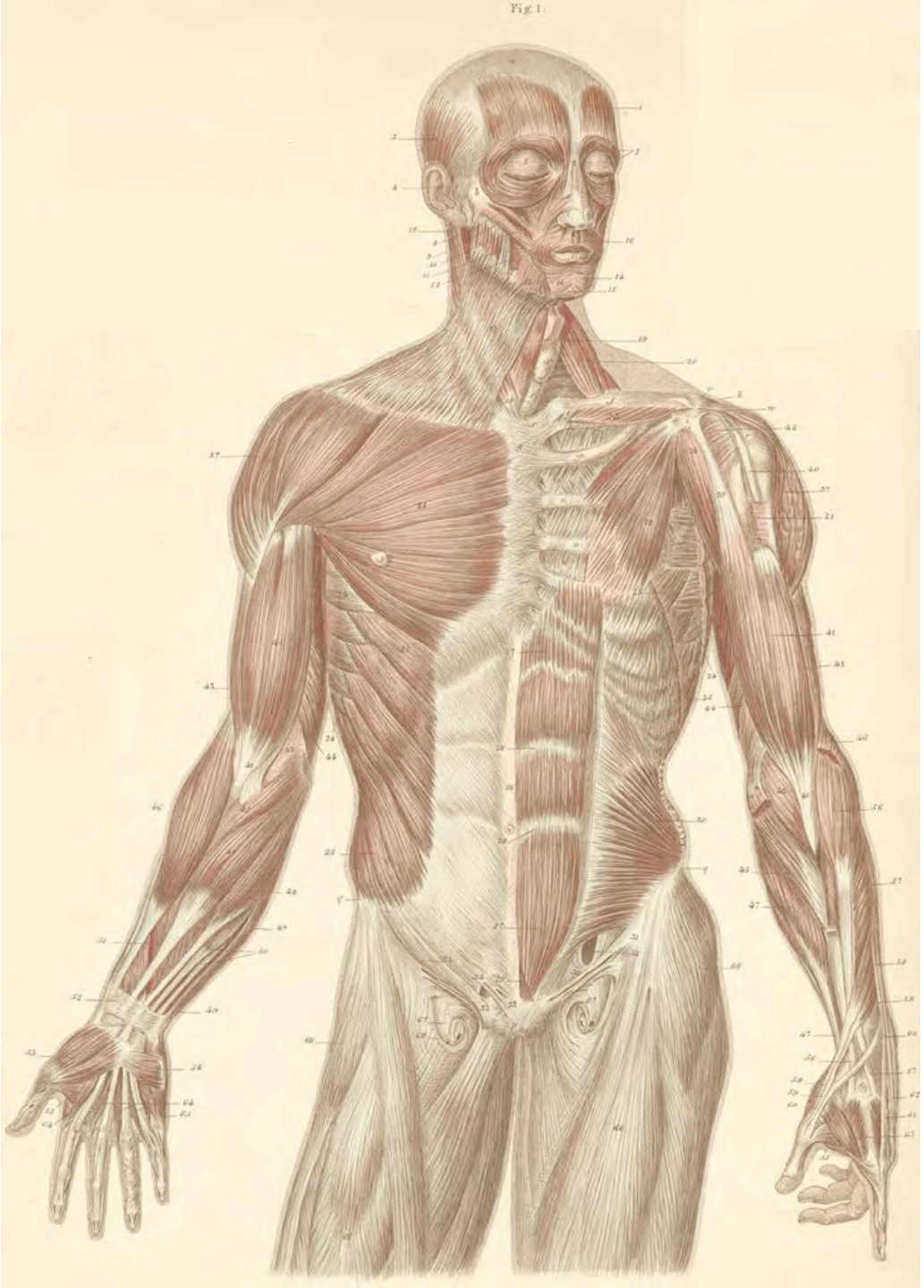

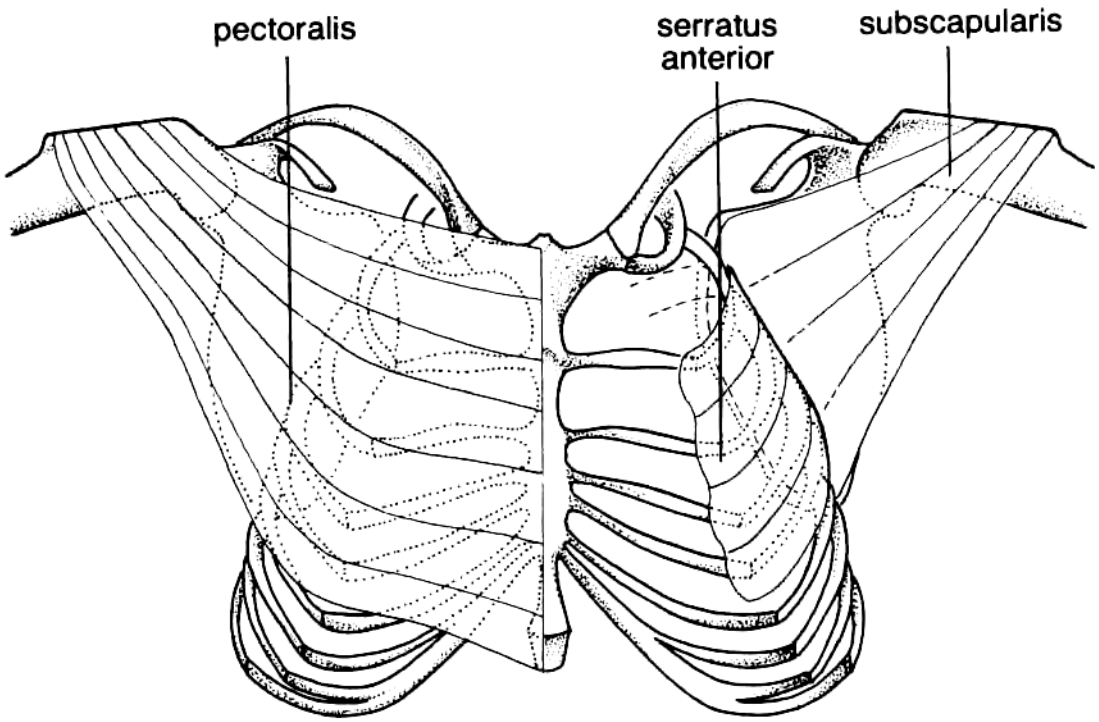
pectoralis
serratus anterior
subscapularis

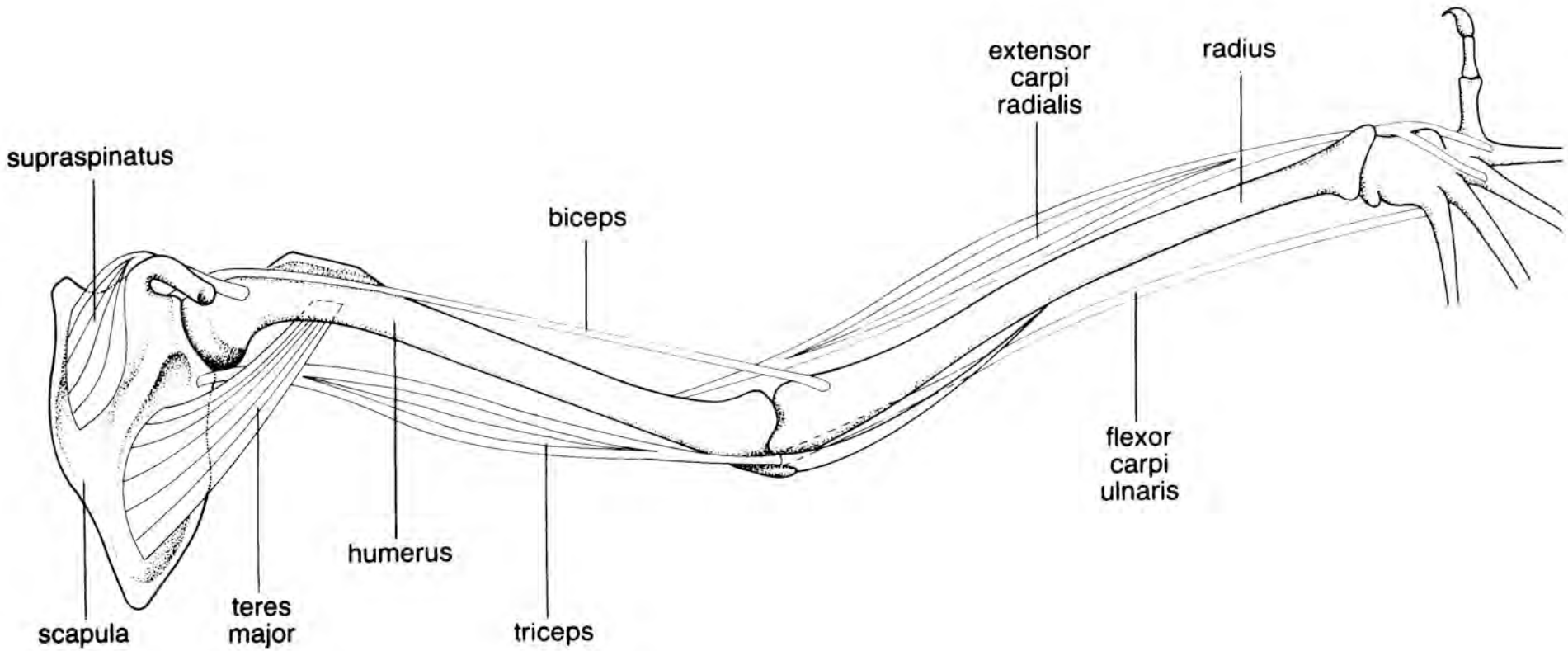
supraspinatus
biceps
extensor
carpi
radialis
radius
flexor
carpi
ulnaris
humerus
scapula
teres
major
triceps

Fig. I.

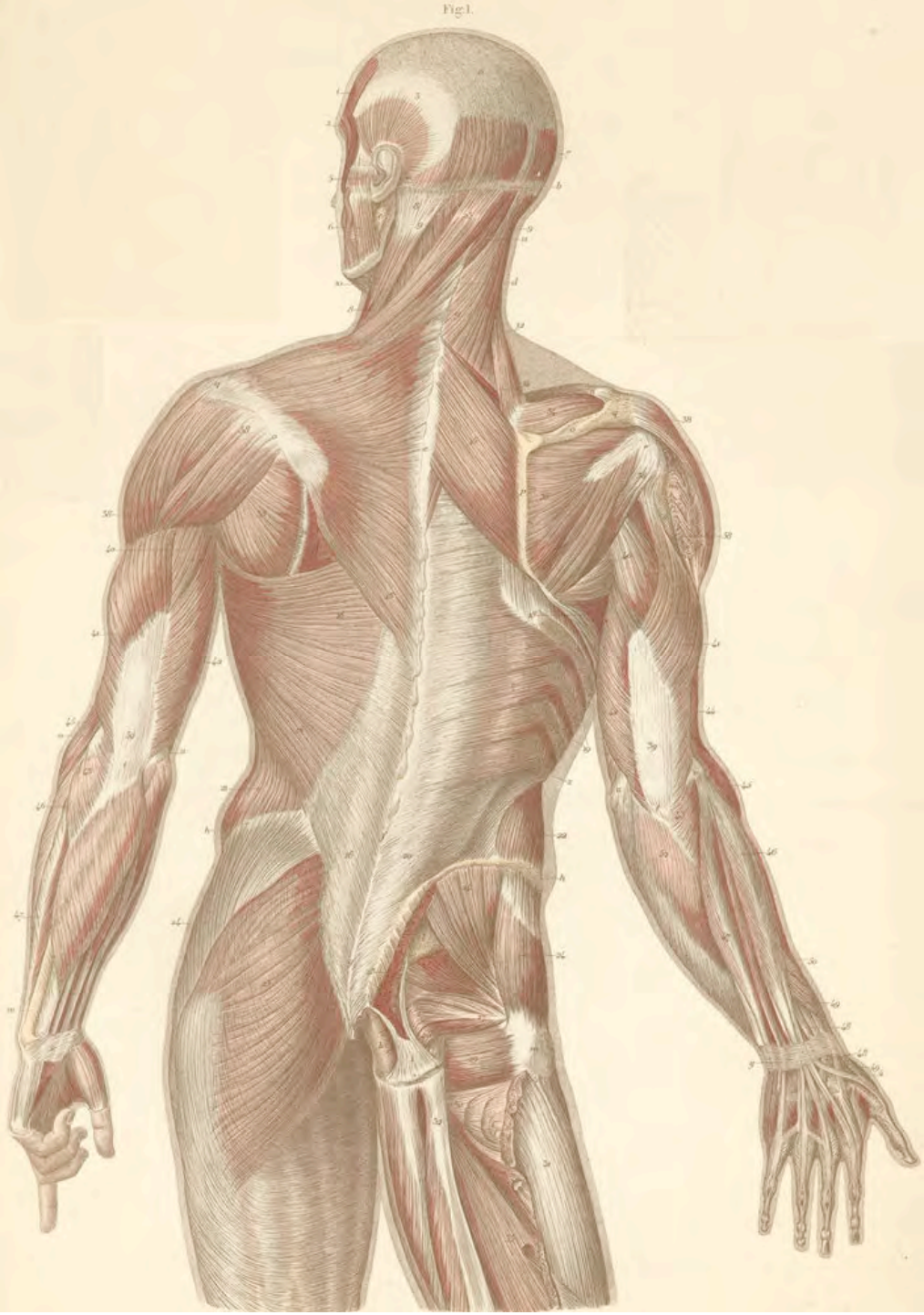

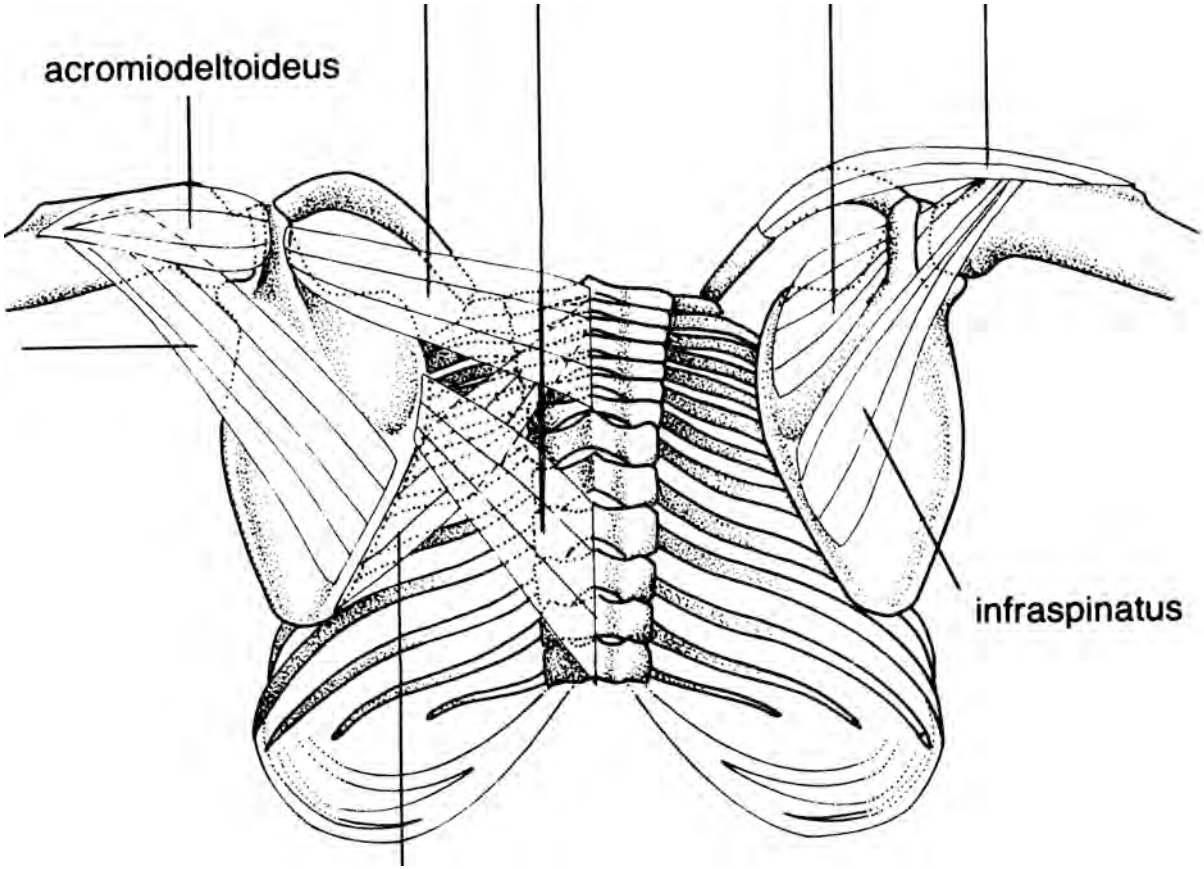
acromiodeltoideus
infraspinatus

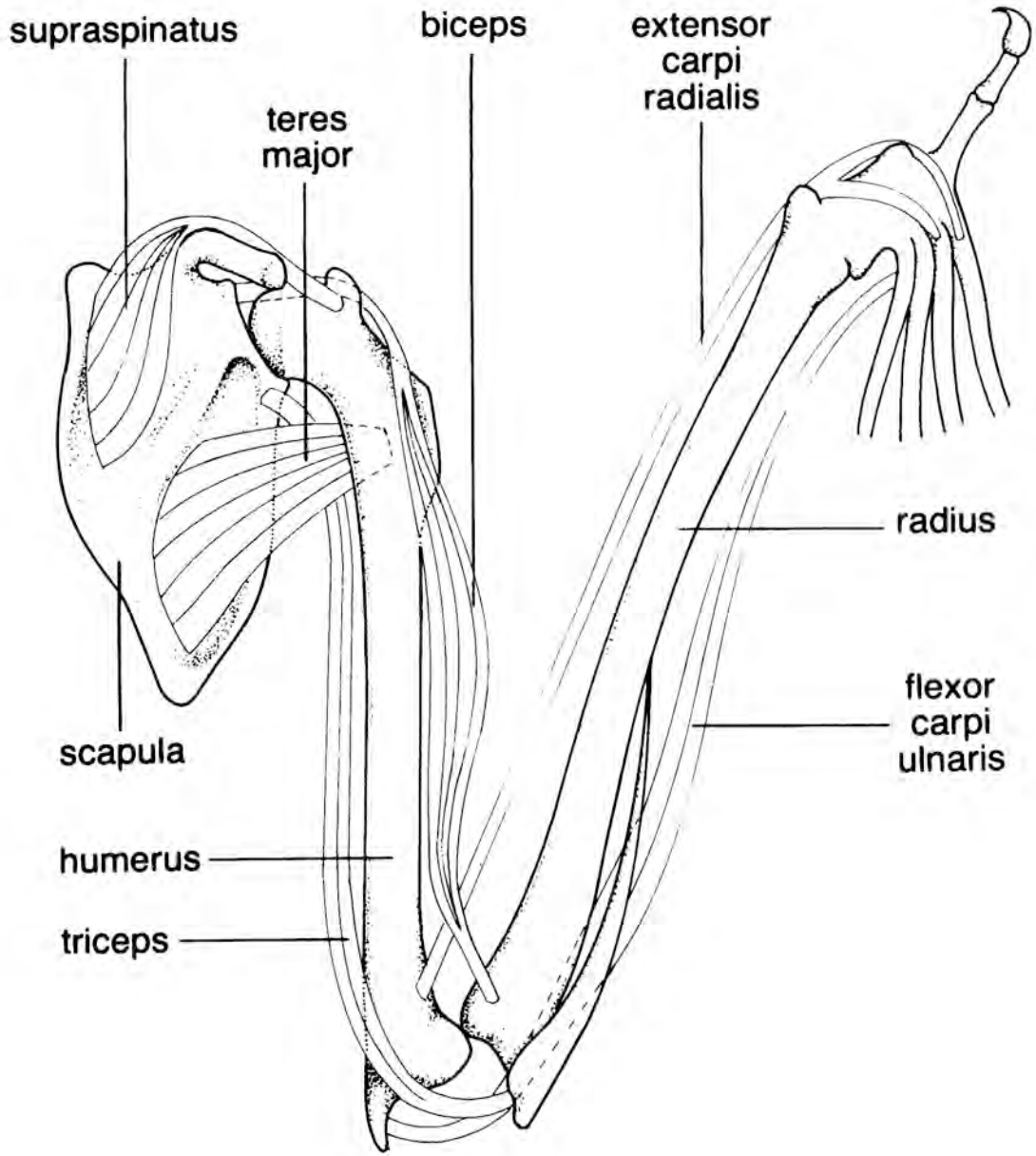
supraspinatus
teres
major
biceps
extensor
carpi
radialis
radius
flexor
carpi
ulnaris
scapula
humerus
triceps

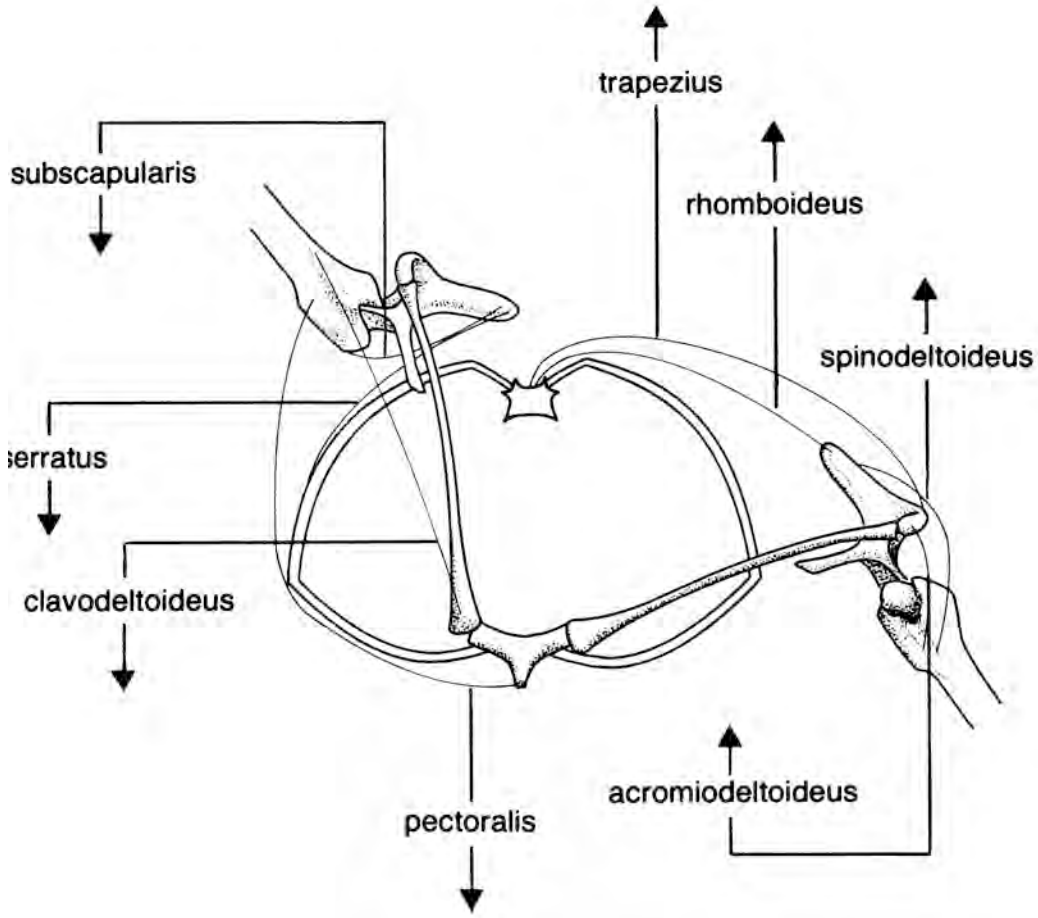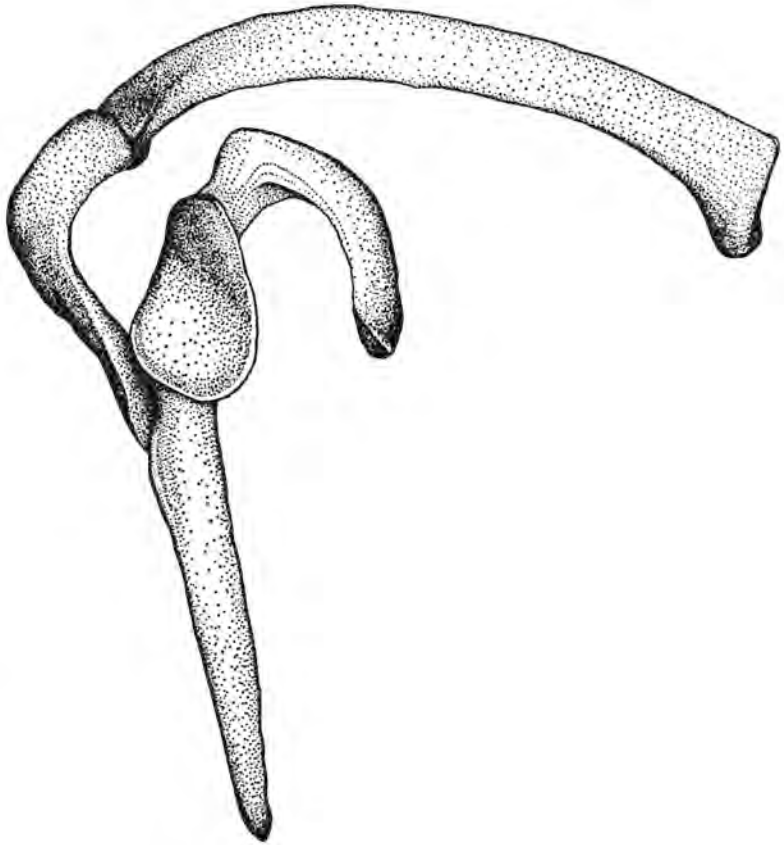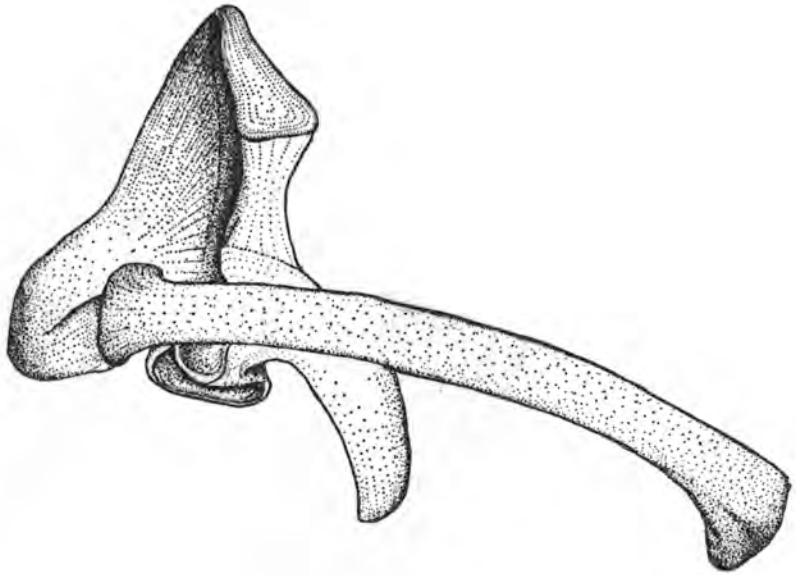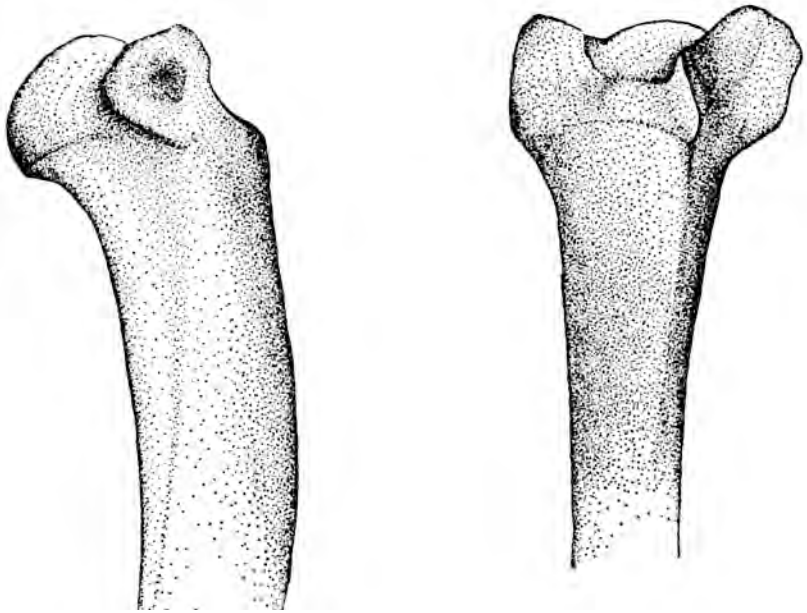
trapezius
subscapularis
rhomboideus
spinodeltoideus
serratus
clavodeltoideus
acromiodeltoideus
pectoralis